

Indolent ulcers in dogs' eyes

G. Janssens⁽¹⁾

SUMMARY

Corneal ulcers are probably the most common problem of the canine eye seen in general veterinary practice. Most of these ulcers result from a variety of traumatic and irritating conditions and usually respond well to medical therapy alone, provided they are not too deep. However, indolent ulcers are different: they are chronic superficial ulcers that result from a structural defect of the cornea and as a result they heal poorly and are usually refractory to medical therapy alone.

This paper was commissioned by FECAVA for publication in EJCAP.

Introduction

The normal cornea is a clear transparent structure composed of several layers: epithelium, subepithelial basement membrane, stroma, Descemet's membrane and endothelium. These layers contribute to the cornea's unique transparency by providing a non-keratinized surface, maintaining control of its water content and of its highly organised arrangement of collagen fibrils and ensuring the absence of blood vessels and pigment. Structural adhesion of the epithelial layer to the underlying anterior stroma is provided by hemidesmosomes and anchoring fibrils that are firmly attached between the basal epithelial cells and the subepithelial basement membrane. The epithelium has a remarkable capacity of regeneration and usually heals within approximately seven days.

Indolent ulcers are also known as chronic epithelial erosion, refractory superficial ulcer, Boxer ulcer, recurrent erosion, refractory epithelial erosion and epithelial basement membrane dystrophy. Because these ulcers are often breed-related, develop spontaneously and may eventually affect both eyes, they may be considered to represent a primary corneal epithelial or superficial stromal dystrophy. Although the exact mechanism of this dystrophy has not been fully resolved, it is generally believed to be caused by a failure of attachment between the basal epithelium to the underlying membrane, which is either absent or abnormal.

Although indolent ulcers may occur in any species, including cats and horses, it is more commonly seen in dogs. It is usually seen

in middle aged to older dogs, without any sex predisposition and can occur in any canine breed, although Boxers and Corgis are predisposed. There is no known mode of inheritance.

Clinical findings

Dogs with indolent ulcers often present with photophobia, blepharospasm and epiphora. The pain may be moderate, but it is minimal compared with other typical superficial ulcers and it usually decreases with the chronic nature of the erosion. A delayed vascular response may be seen with chronic lesions and this is characterised by an ingrowth of superficial blood vessels from the limbus.

Indolent ulcers can be diagnosed by the appearance of a loose or redundant epithelial margin surrounding the ulcer and by eliminating other causes of superficial corneal ulcers.



Fig. 1 The non-attached lip of epithelium in a refractory ulcer may lie flat or may be folded back on itself.

(1) Algemene Dierenkliniek Randstad, Frans Beirenslaan 155, 2150 Borsbeek, Belgium.

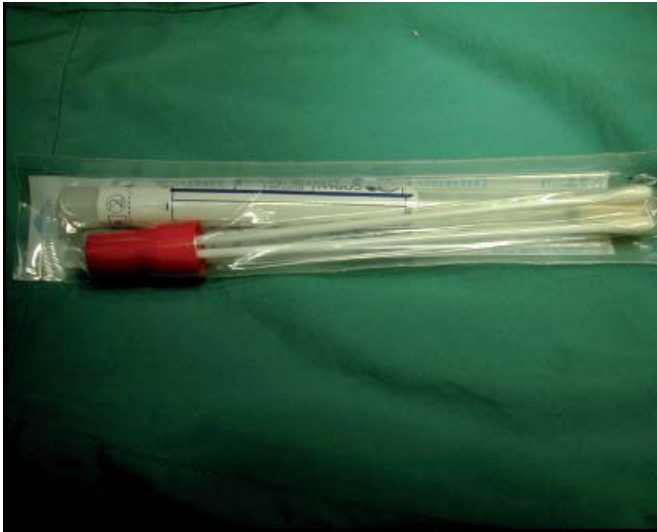

Fig. 2 Dry sterile cotton-tipped applicator.

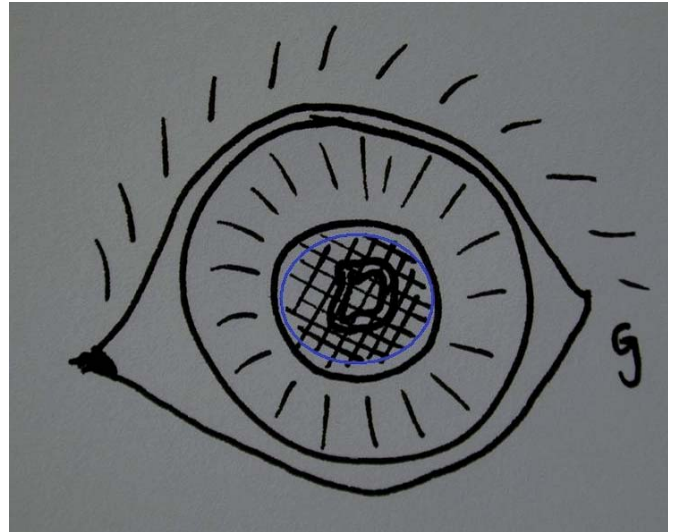


Fig. 3 Diagram of the pattern used to perform grid keratotomy (within blue circle).

A fluorescein stain can assist in the diagnosis as the dye will not only stain the ulcerated area (exposed anterior stroma) but it will also migrate under the loose flaps of the epithelium and stain the surrounding anterior stroma. Consequently, the area of staining is much larger than the size of the actual ulcer. Another test for an indolent ulcer is to rub the margins of a superficial ulcer gently with a dry sterile cotton-tipped applicator: if the loose epithelium can be stripped off the test is positive.

In the case of corneal ulcers one should ALWAYS perform a Schirmer Tear Test (STT). It is important to rule out secondary causes of delayed healing, such as chronic irritation associated with cilia (distichiasis, trichiasis, ectopic cilia) or entropion, facial paralysis, lagophthalmos and infection. Abnormalities of the preocular tear film, such as keratoconjunctivitis sicca and mucin deficiency, may also contribute to ulcer formation. With severe or chronic stromal edema, subepithelial bullae may form. These

bullae may rupture or lift the epithelium off the stroma. If all those causes are ruled out, then persistent corneal erosion is considered to be primary.

Histopathology

During the healing of the epithelial erosion, cell migration and mitosis occur, but abnormal basement membrane material and possibly hyalinized collagen prevent the epithelium from attaching to the underlying stroma. Degeneration of basal epithelial cells, paucity of hemidesmosomes and subepithelial fibrogranular material is seen on histology. The basement membrane is thickened and irregular in appearance. There is separation of basal epithelial cells from their basement membrane.

Fig. 4 Fluorescein stain migrates under a loose flap of epithelium.

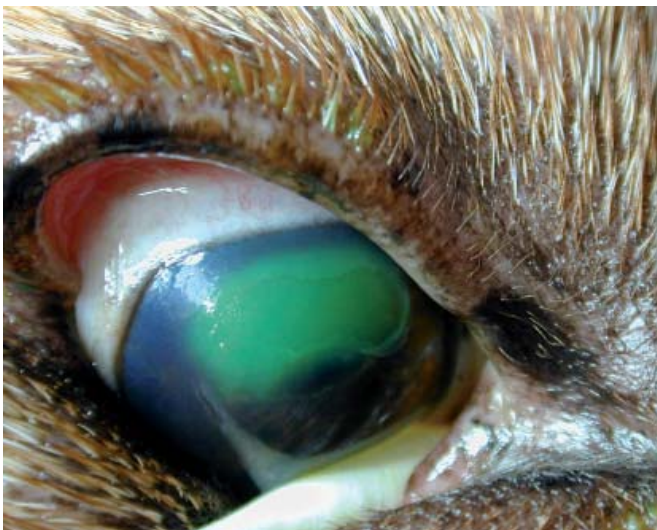
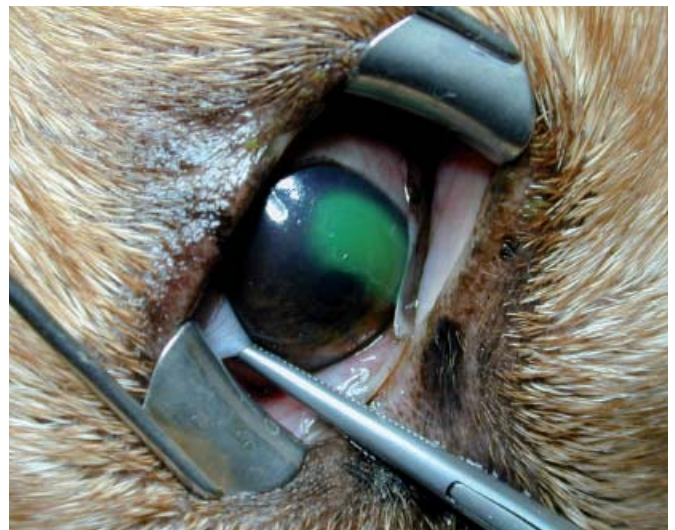
Fig. 5 Eyelid speculum placed for better visualisation of the cornea. The use of the speculum here is for demonstration purposes only and is not routinely performed in practice.



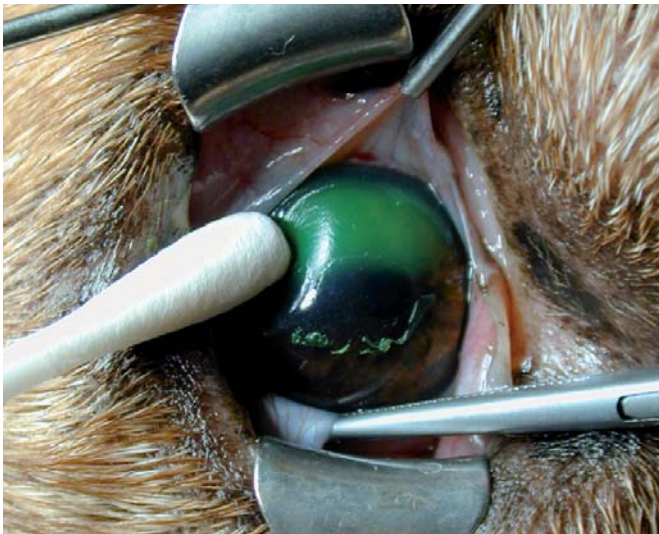

Fig. 6 Debridement with a dry, sterile, cotton-tipped applicator.

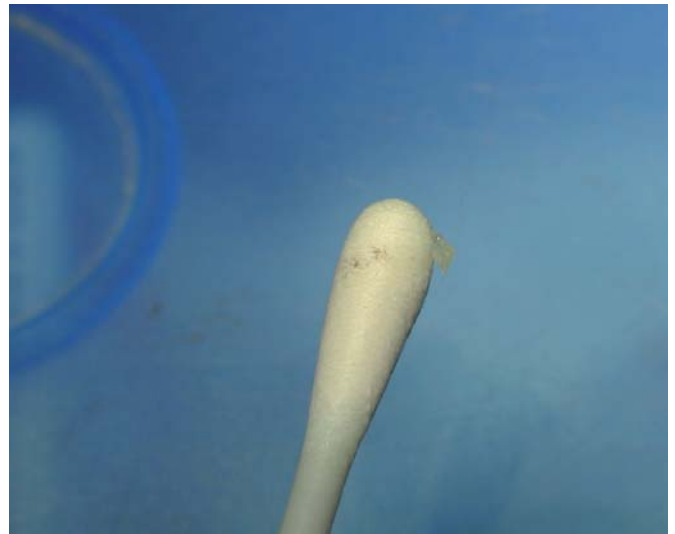

Fig. 7 Removed epithelium.

Treatment

It is important to inform the owners of the progression, expected healing time and possible recurrence of the indolent ulcer in the same eye and even the possibility that the second eye will develop the same problem.

There are several steps that will facilitate healing by removing epithelium and encouraging epithelial attachment.

Debridement and keratotomy

In most dogs, the mechanical debridement of the loose redundant epithelium can be performed with a dry, sterile, cotton-tipped applicator, after application of topical anaesthesia 0.4 % oxybuprocainhydrochloride (Minims, Chauvin, Brussels, Belgium) three times with one minute intervals. With a circular motion, the debridement starts at the apparent edge of the erosion (the rim of the loosened epithelium) and then continues

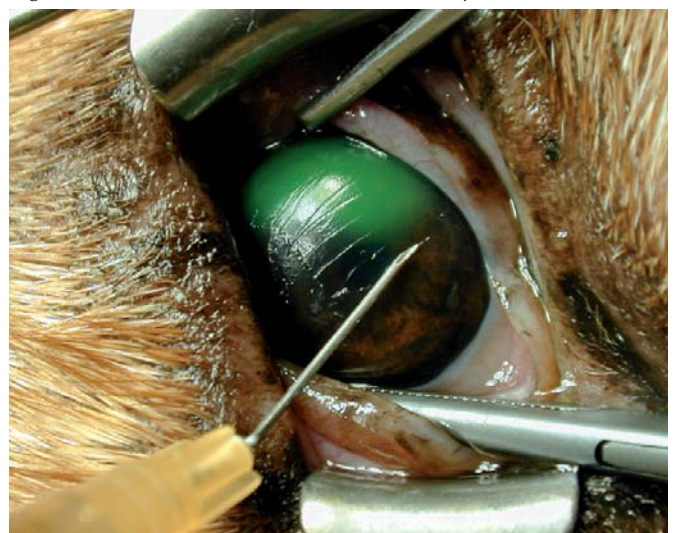
outwards to the true edge of the erosion (the region where the epithelium is properly attached to the underlying stroma). This procedure enlarges the original ulcer.

A linear or grid keratotomy is then performed with a 25-27 gauge needle on a 2 ml syringe or by just holding the needle hub. It is recommended that this procedure be performed with good magnification. Small parallel linear incisions are made in a grid-like fashion through the epithelium and basement membrane to expose the underlying corneal stroma. To do this, the needle should penetrate no further than 0.2-0.3 mm deep and the linear incisions are placed 1-2 mm apart and must extend about 3mm into the normal epithelium surrounding the ulcer. Parallel lines are made in a horizontal plane and then perpendicular to this in a vertical plane. Epithelial cell migration will occur in these lines and will enhance adherence to the corneal stroma. The great advantage of this procedure is that it can be performed

Fig. 8 Completely debrided ulcer.

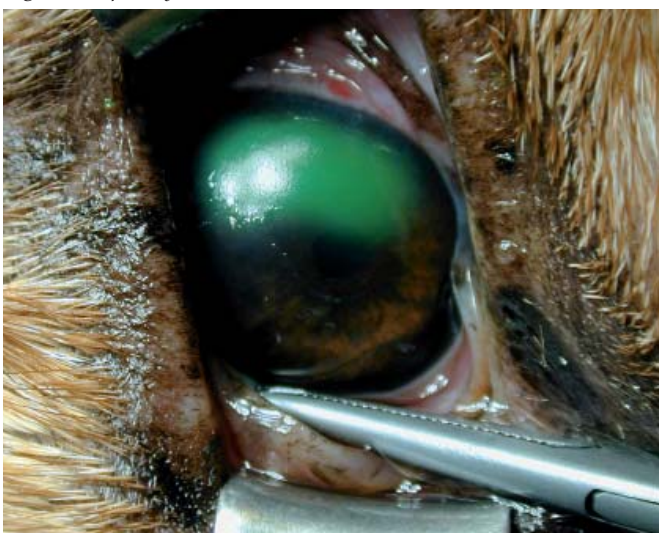

Fig. 9 Parallel lines extend 3mm into normal epithelium.



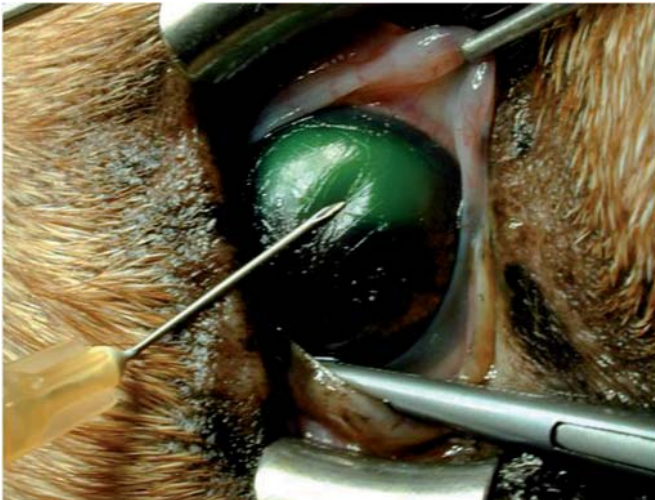


Fig. 10 This is not good positioning of the needle. It needs to be more perpendicular to the corneal surface. It is important not to push hard on the cornea.

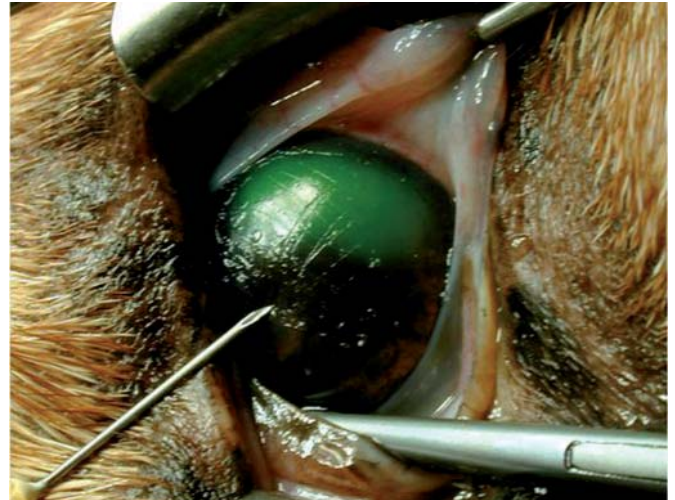


Fig. 11 Two series of lines perpendicular to each other.

in most patients under topical anaesthesia. Only nervous dogs require tranquilization or even general anaesthesia. Healing is expected to occur in 80 to 85% of affected eyes within 10 to 14 days.

Punctate keratotomy is another similar technique. Here, small superficial punctures are made instead of parallel lines. The main disadvantage with this technique is the greater risk of deeper damage to the cornea if the dog suddenly moves. Its success rate is slightly lower than that with the linear keratotomy, perhaps as a result of the reduced stromal surface area exposed with punctate wounds as compared with linear.

Post-operative therapy following these two procedures usually consists of a broad spectrum antibiotic drop or ointment. These medications are used for at least 10 days and a recheck is made every 7-14 days.

Most of the superficial ulcers heal without corneal vascularisation, although in some patients blood vessels may become visible at the limbus and continue to migrate across the cornea towards the lesion at a rate of 0.5-1mm per day. Sometimes there is an extensive invasion of blood vessels in the cornea, forming a raised red corneal plaque. These vessels eventually disappear after several weeks, usually leaving minimal scar tissue afterwards.

Some authors use topical corticosteroids to decrease the growth of those vessels in the cornea once the indolent ulcer has healed. However, we never use them after healing of an indolent ulcer.

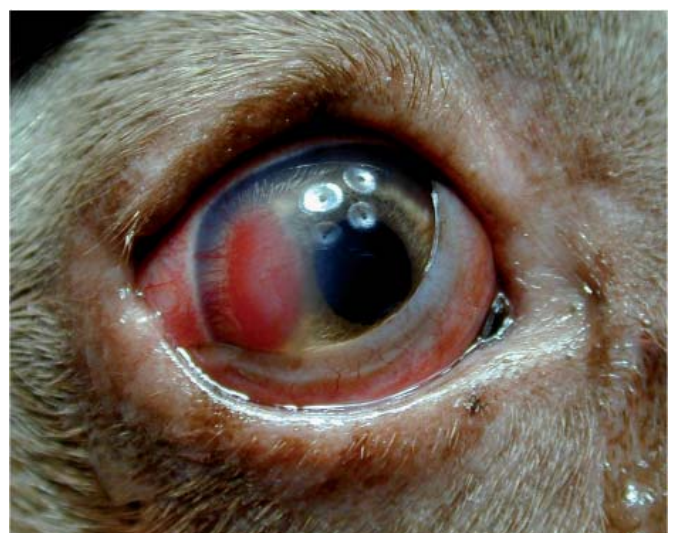In cases of indolent ulcers that have been treated previously with topical corticosteroids, we prefer to perform only a debridement initially and then at the recheck two weeks later, we repeat the debridement and combine it with grid keratotomy if necessary. The reason for this cautious approach is that we do not want to create more corneal lesions at the risk of them not healing properly with the influence of the previously applied corticosteroids.

Superficial keratectomy

This technique is the most invasive and expensive of the surgical procedures for treating indolent ulcers, although it is the most successful. To perform a superficial keratectomy, the patient must be anaesthetised and microsurgical instruments and magnification (preferably an operating microscope) must be used. First, the cornea is debrided as described above. Thereafter, an incision is made into the superficial stroma around the debrided area. One third of corneal thickness is removed from this area. A third eyelid flap can be used to protect the cornea after surgery (although not for the purpose of healing).

In one study performed by Stanley *et al* (1998), a comparison was made between the healing times of three different methods of treatment: debridement with a sterile dry cotton swab, grid keratotomy and superficial keratectomy with a third eyelid flap. The latter gave the shortest healing time (seven days) and gave 100% success of healing after one procedure.

Fig. 12 Example of extensive vascularisation after healing.



Other treatment possibilities

Many other therapies have been described for the management of indolent ulcers. These include chemical cauterization (liquefied phenol, aqueous iodine solution), hydrophilic contact lenses and collagen shields, third eyelid flaps, temporary tarsorrhaphy, tissue adhesives, topical fibronectin, epithelial growth factor, aprotonin and polysulphated glycosaminoglycans.

Note from the author

In the author's opinion, most cases of indolent ulcer heal well with combined debridement and grid keratotomy. We perform a superficial keratectomy in those cases that present with a thick loose epithelial margin around the ulcer. This is because the thickened epithelium is difficult to remove completely with the debridement technique. Superficial keratectomy is also performed in those cases that fail to heal following two treatments of the combined debridement and grid keratotomy.

Acknowledgements

The author is grateful to Edith Hampson for assisting with language translations.

References and further reading

- [1] BENTLEY (E.), MURPHY (J.) - Topical therapeutic agents that modulate corneal wound healing. In: *The Veterinary Clinics of North America, Small Animal Practice*; 2004. p. 623-638.
- [2] PETERSEN-JONES (S.), CRISPIN (S.) - Epithelial basement membrane dystrophy. In: BSAVA, editor. *BSAVA Manual of Small Animal Ophthalmology*. Gloucester: BSAVA; 2002. p. 136-138.
- [3] STANLEY (R.G.), HARDMANN (C.), JOHNSON (B.W.) - Results of grid keratotomy, superficial keratectomy and debridement for the management of persistent corneal erosions in 92 dogs. *Veterinary Ophthalmology*. 1998; **1**: 233-238.
- [4] WHITLEY (R.D.), GILGER (B.C.), - Diseases of the canine cornea and sclera. In: *Veterinary Ophthalmology, 3rd edn*. Ed. K.N. Gelatt: 1999. p. 635-646. Lippincott, Williams and Wilkins, Philadelphia.
- [5] WILKIE (D.A.), WHITTAKER (C.) - Surgery of the cornea. In: *The Veterinary Clinics of North America, Small Animal Practice*; 1997 Vol 27; no 5. p 1067-1077