

Scoring radiographs for canine Hip Dysplasia - The big three organisations in the world

Mark Flückiger Prof. Dr.med.vet., Dipl. ECVDI Dysplasia Committee Zurich
Winterthurerstrasse 270, CH 8057 Zurich. E-mail: HD@vetclinics.uzh.ch

INTRODUCTION

Canine hip dysplasia (CHD) is a developmental malformation of the hip joints resulting in secondary joint disease (arthrosis, arthritis) and corresponding clinical symptoms such as pain and lameness. The major cause of CHD is an excessive laxity of the hip joint, characterized by subluxation of the femoral head out of the acetabulum. The aetiology of CHD is not fully understood. Poor quality connective tissue of the joint capsule may play a crucial role. The disease is hereditary, and current data suggest a major gene theory. Heritability may be up to 95 % (!) depending on breed and population studied. Many breed clubs have established a program to control CHD.

Diagnosis of CHD is commonly based on radiographic findings in large-scale screening of dogs. Radiographic technique has been standardized worldwide. The dog is deeply sedated or anesthetized to guarantee adequate muscle relaxation. Then it is positioned in dorsal recumbence with the hind limbs extended caudally and the femora parallel to the spine, to the table top and to each other. The patellae are centered over the femoral shafts. The severity of CHD is judged based on the degree of subluxation and to a lesser degree on the presence and severity of secondary joint disease. It must be noted though that radiographs do not precisely reflect the genetic make up of a dog itself nor the risk for passing CHD to the offspring.

Internationally 3 somewhat differing scoring modes are in use: The FCI (Fédération Cynologique Internationale), the OFA (Orthopedic Foundation for Animals), and the BVA/KC (British Veterinary Association/The Kennel Club) mode.

The FCI scoring mode

FCI is the umbrella organisation of more than 80 national kennel authorities located in most European countries, in Russia, South America, and Asia. The scientific committee of FCI proposes a 5 grades scoring system from A, reflecting a normal hip joint, to E, indicating severe hip dysplasia. Grades are defined descriptively based on the size of Norberg angle (NA), degree of subluxation, shape and depth of the acetabulum and signs of secondary joint disease. Radiographic evaluation of the hip joints has been implemented as mandatory prerequisite for breeding dogs in many western countries in the last 40 years. Dogs must be at least 1 year of age for official scoring. Hips are usually scored by

a single scrutineer per breed club or within a country with some exceptions. Dogs scoring moderate or severe are banned from breeding in most countries. For mildly dysplastic dogs specific breeding restrictions may apply.

The following FCI classification is based on radiological features noted on a radiograph taken with the hind limbs extended of dogs between 1 and 2 years of age. It is as objective as possible. It may be adopted for older dogs, but secondary arthrotic changes have then to be judged according to the age of the dog. Final grading is based on the worst hip joint (Table 1). The mode of publication of the results depends on the bye-laws established by the individual breed clubs.

The FCI scoring mode

A	<p>No signs of Hip Dysplasia</p> <p>The femoral head and the acetabulum are congruent. The craniolateral acetabular rim appears sharp and slightly rounded. The joint space is narrow and even. The Norberg angle is about 105°. In excellent hip joints the craniolateral rim encircles the femoral head somewhat more in caudolateral direction.</p>
B	<p>Near normal hip joints</p> <p>The femoral head and the acetabulum are slightly incongruent and the Norberg angle is about 105° or The femoral head and the acetabulum are congruent and the Norberg angle is less than 105°.</p>
C	<p>Mild hip dysplasia</p> <p>The femoral head and the acetabulum are incongruent, the Norberg angle is about 100° and/or there is slight flattening of the craniolateral acetabular rim. No more than slight signs of osteoarthritis on the cranial, caudal, or dorsal acetabular edge or on the femoral head and neck may be present.</p>
D	<p>Moderate hip dysplasia</p> <p>There is obvious incongruity between the femoral head and the acetabulum with subluxation. The Norberg angle is more than 90° (only as a reference). Flattening of the craniolateral rim and/or osteoarthrotic signs are present.</p>
E	<p>Severe Hip Dysplasia</p> <p>Marked dysplastic changes of the hip joints, such as luxation or distinct subluxation are present. The Norberg angle is less than 90°. Obvious flattening of the cranial acetabular edge, deformation of the femoral head (mushroom shaped, flattening) or other signs of osteoarthritis are noted.</p>

Table 1: FCI scheme for grading CHD (Dortmund 1991, updated)

The OFA scoring mode

OFA is exclusively representing the USA and Canada. Dogs must be older than 2 years of age for official scoring. A 7 point scoring system is used, dividing the dogs in 2 groups of 3 grades each: Normal hip conformation with excellent, good, and fair score on one side, and dysplastic hip conformation with mild, moderate, or severe CHD on the other side. Hip joints which cannot be assigned to either group are termed undetermined or borderline type and a retake after 6 months is recommended. Diagnostic criteria are again signs of subluxation and DJD. Scoring is done independently by 3 trained radiologists from a consulting pool of certified veterinary radiologists. The score reflects their pooled consensus which is reported back to the owner. Excellent, good and fair hip grades are considered to be within normal limits. Such animals receive an OFA number, and their results are placed in the public domain and are available on the OFA's website. For dysplastic dogs (borderline, mild, moderate and severely dysplastic) a radiographic report is given to the owner. Unless the owner has chosen the open database, dysplastic hip grades are not in the public domain.

NA is not measured and for a long time the 7 grades were not defined precisely and scoring was left to the scrutineers' discretion. Only in the early 90's a written description of the grades was published (www.offa.org). The scheme is voluntary for most breed clubs, and breeder are free to implement the result in their breeding strategy. Details are available under <http://www.offa.org/hipgrade.html>. The following figures and definitions have been taken from the OFA website with minimal modifications.

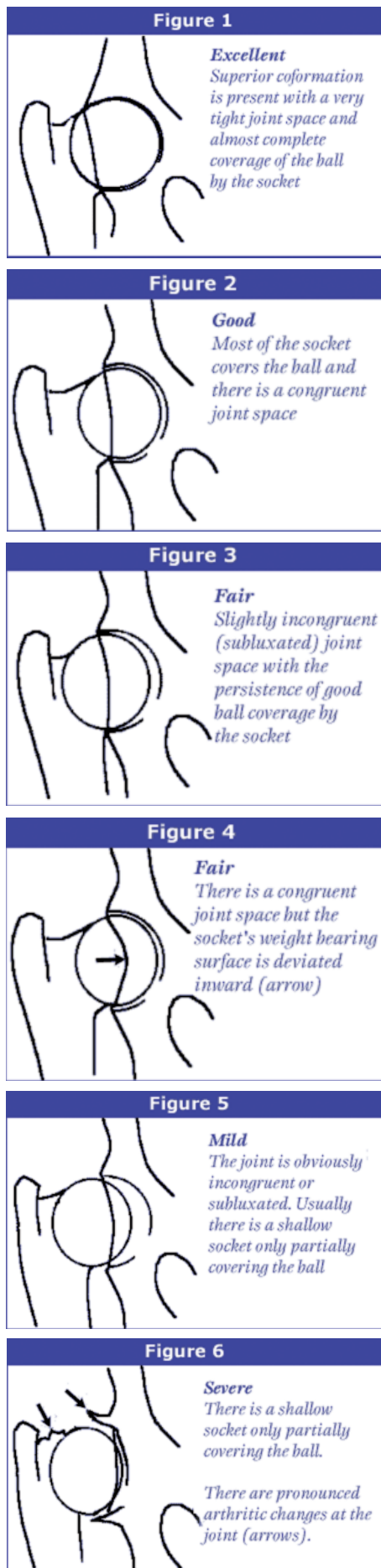
Excellent (Figure 1): Superior hip conformation in comparison to other animals of the same age and breed. There is a deeply seated femoral head which fits tightly into a well-formed acetabulum with minimal joint space. There is almost complete coverage of the acetabulum over the femoral head.

Good (Figure 2): Slightly less than superior but well-formed congruent hip joint. The femoral head fits well into the acetabulum and good coverage is present.

Fair (Figure 3): Minor irregularities are present. The hip joint is wider than a good hip phenotype due to slight subluxation causing a minor degree of joint incongruency. There may also be slight receding of the weight-bearing surface of the dorsal acetabular rim causing the acetabulum to appear slightly shallow

(Figure 4). This can be a normal finding in some breeds however, such as the Chinese Shar Pei, Chow Chow, and Poodle.

Borderline: There is no consensus between the radiologists to place the hip into a given category of normal or dysplastic. There is usually more incongruency present than in a 'fair' but there are no arthritic changes present that would definitively diagnose the hip joint being dysplastic. There also may be a bony projection present on any of the areas of the hip joint illustrated above that can not accurately be assessed as being an abnormal arthritic change or as a normal anatomic variant for that individual dog. To increase the accuracy of a correct diagnosis, it is recommended to repeat the radiographs at a later date (usually 6 months).



Figs. 1-6: Schematic drawings of the 6 OFA gradings.

This allows the radiologist to assess for progressive arthritic changes that would be expected if the dog was truly dysplastic. Most dogs (over 50%) with this grade show no change in hip conformation over time and receive a normal hip rating; usually a fair hip phenotype.

Mild CHD (Figure 5): The femoral head is partially subluxated causing an incongruent and widened joint space. The acetabulum is usually shallow only partially covering the femoral head. There are usually no arthritic changes present and if the dog is young (24 to 30 months of age), a second radiograph may be submitted for re-evaluation when the dog is older. Most dogs will remain dysplastic showing progressive DJD. Since CHD is a chronic, progressive disease, the older the dog, the more accurate the diagnosis of CHD (or lack of CHD).

Moderate CHD: There is significant subluxation present with the femoral head barely seated into a shallow acetabulum. There are secondary arthritic changes usually along the femoral neck and head (remodelling), acetabular osteophytes and various degrees of trabecular bone pattern changes called sclerosis.

Severe CHD (Figure 6): Radiographic evidence of marked dysplasia. There is significant subluxation with the femoral head partly or completely out of a shallow acetabulum. There are massive secondary arthritic bone changes along the femoral neck and head, acetabular rim changes and large amounts of abnormal bone pattern changes.

The BVA/KC scoring mode

BVA/KC is used in Britain, Ireland, and Australia/New Zealand to score each hip joint based on the severity of changes of 9 specific morphological radiographic criteria examined. They are NA, subluxation (2 criteria), shape and depth of acetabulum (5 criteria), as well as shape and signs of DJD at the femoral head and neck (2 criteria). Each criterion is scored from 0 (ideal) to 6 (worst). Final hip score is offered as the sum between 0 and 53 for each hip joint and as the sum of both hips (0-106) (Table 2). Scoring is done by 3 panellists out of a group of certified radiologists or small animal surgeons jointly.

What are the pros and cons of each scheme?

FCI accepts scores made by anyone considering himself expert in the radiological evaluation of canine hip conformation. The individual breed club selects a veterinarian of its preference as scrutineer. Training and competence of the scrutineers vary enormously from self trained practitioners and in some occasions even lay persons to highly skilled certified veterinary radiologists or small animal surgeons. Quality of scoring varies accordingly. Comparison of final grades between countries may become extremely difficult or simply not be possible. Furthermore one single breed within a country may have broken up into different breed clubs and these clubs may work with different scrutineers hampering comparison of the results even within a country. Estimated heritability of an average of 30% (reaching 50% in well designed studies) is somewhat lower than that of BVA/KC, but still offers ample information for selection of breeding stock against CHD.

The website of FCI (www.fci.org) does not provide much help for the breeder, since FCI considers its most important duties to keep track of the standards for each of the 338 recognized breeds, to provide internationally accepted pedigree form (but does not issue any pedigree), to train judges and to collect and list the results of dogs in shows and trials. Good information on the procedure can be found on the website of the Italian fondazione salute animale (FSA) (www.fondazione.saluteanimale.it/CENTRALE/index.html)

The BVA/KC scoring mode

Score per parameter	Norberg Angle (°)	Subluxation	Cranial acetabular edge (CrAE)	Dorsal acetabular edge (DAE)
0	105 and over	Femoral head well centred in acetabulum	Even curve, parallel to femoral head throughout	DAE has slight curve
1	100 to 104	Femoral head centre lies medial to DAE. Lateral or medial joint space increases slightly.	Lateral or medial 1/4 CrAE flat and lateral or medial joint spaces diverge slightly	Loss of S curve only in the presence of other dysplastic change
2	95 to 99	Femoral head centre superimposed on DAE. Medial joint space increase obvious	CrAE flat throughout most of its length	Very small exostosis on cranial DAE
3	90 to 94	Femoral head centre just lateral to DAE. 1/2 femoral head within acetabulum	CrAE slight bilabiation	Obvious exostosis on DAE especially cranially and/or minor "loss of edge"
4	89 to 85	Femoral head centre clearly lateral to DAE. 1/4 femoral head within acetabulum	CrAE moderate bilabiation	Exostosis well lateral to DAE and/or moderate "loss of edge"
5	84 to 80	Femoral head centre well lateral to DAE. Femoral head just touches DAE	CrAE gross bilabiation	Marked exostosis all along DAE and/or gross "loss of edge"
6	79 and less	Complete pathological dislocation	Entire CrAE slopes cranially	Massive exostosis from cranial to caudal DAE

Table 2: BVA/KC scoring mode for CHD

OFA scrutineers are experts in their field and, by reading jointly, diagnostic flaws are highly unlikely to occur. OFA offers extensive advice to breeders on what dog to choose for breeding. Detailed information on each certified dog and its registered sibs and relatives is provided on OFA's website (www.offa.org) making it a powerful tool for breeders.

BVA/KC finally reports the pooled consensus brought up by 3 highly experienced and skilled scrutineers who guarantee a correct reading. Final hipscore reaches a heritability of up to 70%, which is high for a system based on standard radiographs in a non-stressed position. Final score is given as a figure from 0 for an excellent to 106 for a highly dysplastic and severely arthrotic hip joint. No translation of the numerical score into a dysplasia grade is provided. BVA recommends breeding dogs with a score of 5 or less (total score for both joints < 10) or clearly below breed mean score. Breed mean score is listed and

regularly updated for each breed on the BVA's website (www.bva.co.uk/public/chs/bms2006.pdf). Breeding from dogs scoring more than 15 (total score for both joints > 30) is undesirable. Additional information regarding health and diseases of selected breeds is available from (www.thekennelclub.org.uk).

The scheme is completely voluntary and selection of breeding dogs is in the discretion of the owner. Even severely dysplastic dogs may be used. In the mid 90's more than a quarter of all matings included a non-tested parent.

Scores and gradings of the 3 big players can be compared, but direct translation from the UK system into a descriptive grading is only possible if the individual score of each parameter is known (Table 3). In Switzerland the numerical score is not released to the public. For the owner the score is transformed into a FCI degree.

Cranial effective acetabular rim (CrEAR)	Acetabular fossa (AF)	Caudal acetabular edge (CaAE)	Femoral head & neck exostosis	Femoral head recontouring
Sharp, clean cut junction of DAE and CrAE	A fine bone line curves medial and caudal from caudal end of CrAE	Clean line	Smooth rounded profile	NIL
Indistinct junction of DAE and CrAE	Slight increase in bone density medial to AF. "Fine line" hazy or lost.	Small exostosis at lateral CaAE	Slight exostosis in "ring form" and/or dense vertical line adjacent to the trochanteric fossa ("Morgan Line")	Femoral head does not fix in circle due to exostosis or bone loss.
Very small exostosis or very small facet	Fine line lost in AF and ventral AE hazy due to new bone. Notch at CaAE clear	Small exostoses at lateral and medial CaAE	Slight exostosis visible on skyline and/or density on medial femoral head	Some bone loss and/or femoral head/neck ring of exostosis
Facet and/or small exostosis and/or slight bilabiation	Incomplete remodelling of acetabulum with medial face lateral to AF. Ventral AE lost. AF hazy. Notch irregular	Large exostosis and narrow notch at CaAE	Distinct exostosis in "ring formation"	Obvious bone loss and distinct exostosis giving slight conical appearance
Obvious facet and/or obvious exostosis and/or moderate bilabiation	Marked remodelling. Medial face of acetabulum clearly lateral to AF. Ventral AE lost. Notch partly closed.	Marked exostosis and "hooking" of lateral end of CaAE	Obvious complete collar of exostosis	Gross remodelling. Obvious bone loss and exostosis gives mushroom appearance
Gross exostosis and/or facet and/or gross bilabiation	Gross remodelling. Dense new bone throughout acetabulum. CaAE notch lost and AF obscured	Gross distortion due to mass of new bone in acetabulum. Notch lost completely	Massive exostosis giving mushroom appearance	Very gross remodelling with marked bone loss and much new bone
Complete remodelling of CrEAR. Massive exostosis and/or gross facet	Complete remodelling and new articular surface, well lateral to AF. Notch lost.	Void	Massive exostosis and infill of trochanteric fossa and below femoral head	Femoral head is improperly shaped due to maldevelopment of femoral head centre

FCI	Germany (except SV)	Germany SV (GSD)	UK, AU, NZ (worse joint)	Switzerland (worse joint)	USA (OFA)
A, normal	A1	a, normal	0	0	excellent
	A2	a, normal	1-3	1-2	good
B, borderline	B1	a, fast normal	4-6	3-4	good
	B2	a, fast normal	7-8	5-6	fair
C, mild	C1	a, noch zugelassen ¹⁾	9-12	7-9	borderline ²⁾
	C2	a, noch zugelassen	13-18	10-12	mild
D, moderate	D1	D1	> 18	13-15	moderate
	D2	D2		16-18	moderate
E, severe	E1	E1		19-21	severe
	E2	E2		22-24	severe

1) noch zugelassen - German, but internationally understood expression 'tolerated for breeding'.

2) Correct scoring not possible. Recheck after 6 months recommended.

Table 3: Comparison of CHD scoring

OFA	FCI (Europe)	BVA/KC (UK/Australia) (score = sum of both hips)	SV (Germany)
Excellent	A-1	0-4 (no > 3/hip)	a, normal
Good	A-2	5-10 (no > 6/hip)	a, normal
Fair	B-1	11-18	a, near normal
Borderline	B-2	19-25	a, noch zugelassen ¹⁾
Mild	C	26-35	a, noch zugelassen ¹⁾
Moderate	D	36-50	Moderate HD
Severe	E	51-106	Severe HD

Table 4: Comparison of CHD scoring, list provided by OFA

It is important to understand that each of the 3 scoring schemes can be used for selecting breed dogs against CHD. The reliability of the final score depends heavily on the skills of the scrutineers. Both OFA and BVA/KC scrutineers are experts and their gradings are undisputed. The same is true for scrutineers from many western and northern countries in Europe, while in others the dogs' scores may differ markedly from reality, and are often stated better than one would expect.

The impact of the data on the quality of the offsprings' hip joints lies mainly in the breeders' hands and their ability to understand

and accept the results and to adhere to the recommendations of the geneticists. These recommend not to use dysplastic dogs for breeding. This implies that even dogs with a hip score C or mild degree of CHD should not be used. A concept which makes sense when considering that controlling any disease of unclear heredity is based on the elimination of carriers from the breeding stock. Unfortunately particular breed clubs with large numbers of dogs (German Shepherd dogs, Retrievers) do not comply with advice. The vast majority of their dogs are accepted for breeding despite the fact that a substantial percentage of dogs within the breed are dysplastic, when unbiased screening data are considered. By accepting most dogs within a population for breeding no improvement of hip conformation can be achieved.

References

- BRASS (W.) et al. *Kleintierpraxis* 1978, **23**: 169-180.
BVA/KC homepage: www.bva.co.uk/public/chs/hip_scheme.asp
FSA homepage: www.fondazionealutearmale.it/CENTRALE/index.html (in Italian)
GIBBS (C.) 1997: *Vet. Rec.* **141**: 275-284 (Erratum in: *Vet. Rec.*, 1997, **141**: 576.)
GUTMANN (M.) *Thesis* 2003, Univ. of Giessen, Germany
OFA homepage: www.offa.org
WILLIS (M.B.) *JAVMA*, 1997, **210**: 1480-1482